Oktober 2007

LASER ASSISTED CORNEAL OPHTHALMIC SURGERY

HEALTH TECHNOLOGY ASSESSMENT UNIT

MEDICAL DEVELOPMENT DIVISION

MINISTRY OF HEALTH MALAYSIA

012/07

Prepared by:
Dr Mohd Aminuddin Mohd Yusof
Principal Assistant Director
Health Technology Assessment Unit
Ministry of Health Malaysia
Oktober 2007

Reviewed by:
Datin Dr Rugayah Bakri
Deputy Director
Health Technology Assessment Unit
Ministry of Health Malaysia
Oktober 2007

1. INTRODUCTION

There are many corneal pathological conditions that are treated by surgery i.e. refractive error, graft transplantation, keratoconus, corneal ulcer / scar, etc. For that matter, surgical methods have become more accepted practice to correct refractive errors. Thus, there has been increasing demand for technological improvements that will decrease complications and improve patient outcomes. This includes the use of laser and those widely use in ophthalmology employ nanosecond (10^{-9} seconds) and longer pulses to create several types of ocular tissue interaction including photoagulation (argon laser), photoablation (excimer laser) and photodisruption (Nd:YAG laser).[1] For example, a common surgical procedure in refractive correction is LASIK (laser in situ keratomileusis). It applies excimer laser ablation on corneal stroma beneath a mechanically (blade) generated anterior corneal flap.

Although corneal flaps have traditionally been created with mechanical microkeratomes, more recent technology, femtosecond laser, has emerged as an alternative for that purpose and has revolutionized the creation of flaps for LASIK procedures.[1, 2] The US Food and Drug Administration (FDA) has approved the use of this technology in January 2000.[1, 2] Due to the flexible delivery system of this technology, it allows intrastromal corneal surgery (e.g. intrastromal ablation without a flap) to be done and makes it useful for other refractive and corneal procedures.[1] The femtosecond laser is produced and marketed by IntraLase worldwide, and 2010 Perfect vision and Ziemer Ophthalmic Systems in Europe.[2]

This technology review has been requested by Dr. Asmayani bt. Khalib of Unit Sumber Perubatan, Bahagian Program Perubatan, Kementerian Kesihatan Malaysia. The review includes all ophthalmic conditions that involve laser as part of its treatment with specific focus on femtosecond laser. The safety and effectiveness of the technology has been assessed thoroughly through appraisal of the best available evidences.

2. OBJECTIVE /OBJECTIVES

To retrieve evidence on the safety and effectiveness of laser-assisted corneal ophthalmic surgery.

3. TECHNICAL FEATURES

Methods of flap creation have changed over the years. The mechanical microtome and femtosecond laser keratome have different mechanisms of action to create corneal resections.[3] The critical components in laser in-situ keratomileusis / LASIK surgery remain the same: safety, efficiency, predictability and biochemical stability. In fact, LASIK has become the most popular corneal refractive surgery and one of the critical steps in this procedure is the creation of the corneal flap.

Excimer laser is a form of ultraviolet chemical laser that has been invented in 1970 and thus has been used much earlier than any other lasers in the field of ophthalmology.[4] It typically uses a combination of an inert gas (Argon, Krypton or Xenon) and a reactive gas (Fluorine or Chlorine). Under the appropriate conditions of electrical stimulation, a pseudo-molecule called a dimmer is created, which can only exist in an energized state and can give rise to laser light in the ultraviolet range. This light is well-absorbed by biological matter and organic compounds. Rather than burning or cutting material, the excimer laser adds enough energy to disrupt molecular bonds on the surface tissue, which effectively disintegrates into the air in a tightly controlled manner through ablation. Thus, excimer lasers have the useful property that they can remove exceptionally fine layers of surface material with almost no heating or change to the remainder of the material which is left intact. These are well-suited to the precision of delicate surgeries e.g. LASIK. Excimer lasers are usually operated with a pulse rate of around 100 Hz and a pulse duration of ~10 ns.

Laser with ultrafast pulses have been developed to decrease the energy necessary to incise tissues and damage to surrounding tissues.[1, 2] It uses an infrared (1053 nm) scanning pulse focused to 3 µm with an accuracy of 1 µm to cut a spiral pattern in the corneal stroma creating precise lamellar flaps for LASIK. Femtosecond laser, which uses

such technology in the form of focusable laser[2] and pulse duration in the range of 10^{-15} (short duration energy pulses) second range[1], provide potentially safe advantages because they cut flaps precisely by photodisrupting tissue and with uniform thickness. The contiguous pulses used in the laser are placed at a precise depth within the cornea and the wavelength of light is transparent to the cornea.[2] With the energy and firing pattern controlled by computer, the laser is capable of cutting tissue at various depths and patterns. It is able to create full-thickness corneal incisions with customized graft-edge profiles for both donor and recipient corneas i.e. in femtosecond laser-assisted keratoplasty (FLAK).[2] It also improves precision in determining flap diameter and thickness and may allow programming of the angulation of the flap periphery. This theoretically provides better flap stability and thus prevent epithelial invasion.

The femtosecond laser creates plasma inside the corneal stroma without interference with the epithelium. It essentially vaporizes small volumes of tissue by photodistruption (laser-induced optical breakdown).[1], [2] This then produces plasma, shock wave, cavitation, and gas (CO_2 and H^2O) bubbles. Each impact of one to three µm produces a cavitational bubble of a maximum 10 µm in diameter. Flap periphery can be programmed to have an angulation with respect to the flap plane. After resecting the corneal flap, refractive ablation with the excimer laser was performed.

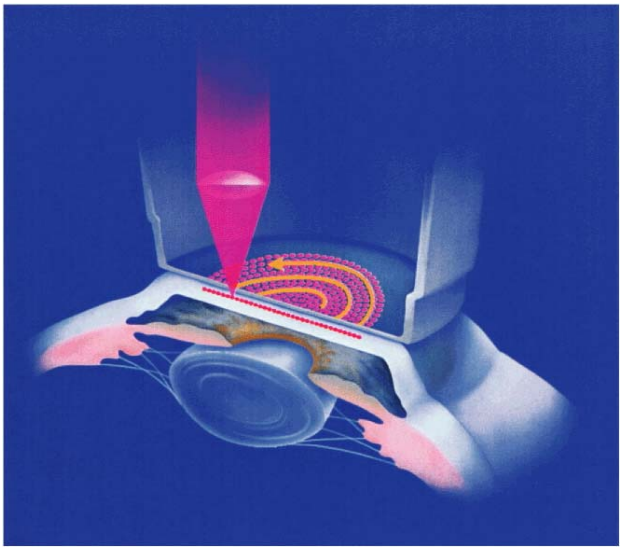

Figure 1. LASIK flap creation The figure demonstrates the application of femtosecond laser pulses to the applanated cornea.

Unlike lasers employing visible wavelengths, the ability of the femtosecond laser to cut corneal tissue is less hampered by optical haze.[2] Thus, it makes the technology more useful in treating oedematous or otherwise opacified corneas. The laser spots maybe fired in a vertical pattern for trephination (side) cuts or in a spiral or raster (zigzag) pattern to achieve lamellar cuts. Lamellar flap thicknesses created by femtosecond laser can be much thinner than mechanical microkeratome flaps. Suction rings and applanation glasses are disposable for the femtosecond lasers, possibly decreasing contamination and saving time used for sterilization.[1] Above all, improved epithelial preservation is a significant safety advantage for the femtosecond laser. The disadvantages of using femtosecond laser for LASIK relate to the need for two lasers and the potential for extra costs.[1]

Specific applications of femtosecond laser are as follows[2]:-

i. Intracorneal ring segments (e.g. Intacts)

Intacts are curved (crescent-shaped arc) clear polymethylmethacrylate ring segments that are implanted in the peripheral intracorneal areas to correct of up to -3.50 Diopters of myopia. Using mechanical spreader, the procedure has risks of corneal perforation, shallow or uneven implant placement, and extension of channel incisions. Use of femtosecond laser for creation of channels for Intacs insertion enhances safety by providing greater consistency of depth and uniformity of the channel.

ii. Astigmatic keratectomy

Traditional penetrating keratoplasty can result in high levels of astigmatism which may not be correctable with spectacles or contact lenses. The femtosecond laser may be useful in correcting high astigmatism following penetrating keratoplasty. In other scenario, a standardized technique has been developed to use the femtosecond laser to create corneal incisions in a peripheral wedge-shaped orientation.

iii. Keratoprosthesis

The success rate of penetrating keratoplasty is low in patients with past or chronic inflammation and with repeated graft failures. These patients may benefit from

implantation of an artificial cornea or keratoprosthesis in which femtosecond laser can be used in the procedure.

iv. Keratoplasty

Femtosecond laser-controlled software is customizable to achieve different graft geometric configurations, potentially allowing for sutureless, self-adhesive keratoplasty.

a. Anterior lamellar keratoplasty (ALK)

ALK is indicated for management of anterior corneal dystrophies, degenerations, ulcers and scars. Benefits of renewed-interest ALK include less invasive (not intraocular) surgery and reduced risk of rejection. The femtosecond laser, with the ability to perform precise corneal dissections at a variety of depths and orientations, is a powerful tool in the development of new lamellar keratoplasty technique. Reported complications of laser-assisted ALK are slow growth of epithelium over the graft and neovascularization.

b. Posterior lamellar keratoplasty

Complications of full-thickness keratoplasty include high or irregular astigmatism, slow visual recovery, traumatic wound dehiscence and suture-related problems. The femtosecond laser has not been used to perform PLK in clinical trials.

c. Descemet's stripping endothelial keratoplasty

This procedure allows removal of the diseased endothelium while leaving posterior cornea intact. This technique eliminates the difficult dissection of the lamellar pocket required in PLK and creates a smoother donor-recipient interface.

d. Femtosecond laser-assisted keratoplasty

Penetrating keratoplasty (PKP) involves use of manual trephines to incise donor graft button and remove the diseased recipient cornea. A skilled trephination technique is needed to avoid irregular or decentered cuts which can lead to astigmatism and refractive error post-operatively. The limitations of custom-shaped manual keratoplasty include imprecise and tedious dissection of donor and recipient corneal edges, leading to potential for graft-host wound mismatch. However, the femtosecond laser-assisted keratoplasty application allows a posterior side cut, lamellar cut and anterior side cut to

be created in both the recipient and donor corneas. Two or more of these cut segments can be turned on or combined to create patterns for shaped keratoplasty (refer **Figure.2**).

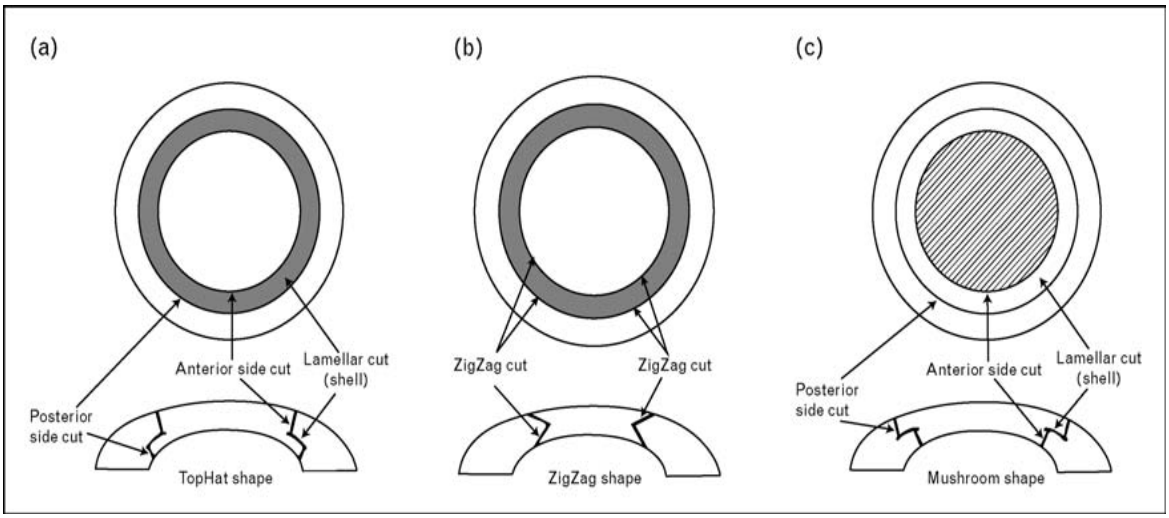

Figure 2. Schematic representation of shaped keratoplasty incisions with (a) top hat, (b) zigzag pattern and (c) mushroom.[2]

4. METHODOLOGY

4.1 Search Methods

Literature were searched through scientific electronic databases, which included Pubmed, OVID, Science Direct and Springer Link, and as well as general databases such Yahoo and Google.

The search strategy used the terms, which are either used singly or in various combinations: “Excimer Laser” AND “Femtosecond Laser” , “Femtosecond Laser” AND (‘Safety” OR “Adverse events”), “Femtosecond Laser” AND “Anterior Lamellar Keratoplasty”, “Femtosecond Laser” AND “Posterior Lamellar Keratoplasty”, “Femtosecond Laser” AND “Keratoconus”, “Femtosecond Laser” AND “Astigmatism Keratectomy”, “Femtosecond Laser” AND “Superficial Cornea Scarring”, “Femtosecond Laser” AND “Corneal Transplant” “Femtosecond Laser” AND “Cost Effectiveness”.

Limitation in search was only on English articles.

4.2 Selection of studies

All primary papers, systematic reviews or meta-analysis pertaining to safety, effectiveness and cost effectiveness on laser assisted corneal ophthalmic surgery were included in this study.

A critical appraisal of all relevant literatures was performed and the evidence level graded according to the modified Catalonian Agency of Health Technology Assessment (CAHTA).

5. RESULTS AND DISCUSSION

5.1 Safety

Epithelial preservation is a key factor in healing and subsequent avoidance of post-operative complications.[3] Significant variability favouring the laser keratome has been reported with regard to loose epithelium or epithelial slides and epithelial defects during flap creation.[5 Level 8] The IntraLase femtosecond laser requires no moving instrumentation during the procedure and this explains better epithelial preservation seen with it. Guy M. Kezirian and Karl G. Stonecipher found that loose epithelium was encountered in 9.6% of eyes in the Carriazo-Barraquer group and 7.7% of eyes in the Hansatome group but none in the eyes in IntraLase group (p=0.001).[5 Level 8] Having said that, all three devices were found to have similar rates of Best Spectacle Visual Acuity (BSCVA) loss, which was also a safety measure in flap creation.

There is a growing concern about iatrogenic corneal ectasia after LASIK even though it is relatively uncommon.[3] Strategies to prevent it include preserving a minimum residual stromal bed of 250-300 µm, which makes flap thickness predictability a critical factor to LASIK safety. Ioannis G.Pallikaris et al noted that there was no patient with attempted correction than 8.00 diopters or a residual corneal bed thickness more than 325µm had post-LASIK ectasia.[6 Level 8] However, as there was statistically significant positive correlation (r=0.62) with age, it was suggested that the development of ectasia could be attributed to mechanisms other than corneal weakening by tissue subtraction e.g. changes during aging.

Unexpectedly thick flaps and variable thickness have been reported with the flaps created with a mechanical microtome being thinner in the centre and thicker in the periphery.[3] However, femtosecond laser flaps have been shown to be of more uniform thickness. In a related study, IntraLase flaps were significantly thinner ($p<0.01$) and varied less in thickness ($p<0.01$) than flaps created with other devices.[5 Level 8] The better predictability of flap thickness with this device can be expected to reduce the incidence of ectasia. It may also ensure greater residual stroma in patients requiring second operations. As shown in **Figure 3**, it is evident that the flap uniformity favours the planar IntraLase femtosecond laser keratome in comparison to the meniscus-shaped mechanical microkeratome created flap.[3]

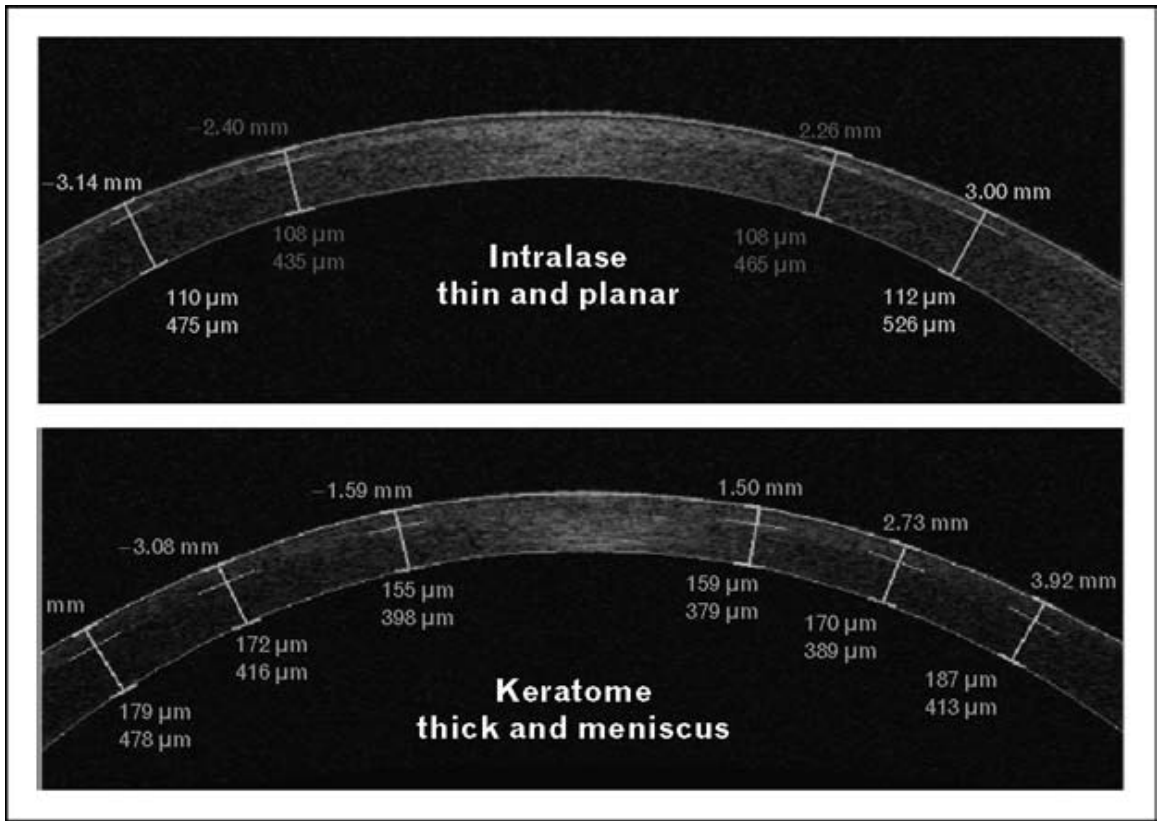

Figure 3. Zeiss Visante imaging system and flap uniformity[3]

Penetrating keratoplasty (PKP) is probably the most successful transplantation procedure today. However, one theoretical problem with non-mechanical trephination for PKP is the lens changes induced by intra-operative secondary radiation, with potential effect on

cataract formation. In a 2000 study on lens opacities, apart from its optical advantages, non-mechanical (Excimer laser) corneal trephination appeared to have no adverse impact on cataract formation after PKP for keratoconus.[7] [Level 2] The difference in incident opacities between the technique and mechanical trephination was not statistically significant (p= 0.833). In fact, there was no differences between the two trephination methods in a 5 year Kaplan–Meier cumulative risk of lens opacity formation (p= 0.763 for cortical opacities, p =0.530 for posterior opacities). The intense steroid regime used to prevent immunologic rejection of the graft may elucidate the apparently high ratio of posterior subcapsular cataracts observed in the study.

Certain side-effects are unique to the femtosecond laser e.g. Transient Light Sensitivity Syndrome.[3, 8] [Level 8] It was first reported in 2001 when higher laser pulse energy was used to create the flaps. It presents in patients after two to six uneventful LASIK surgery as good visual acuity with delayed onset of photophobia, which is transient and resolves spontaneously. Patients complaint extreme sensitivity to indoor lights and computer screens. Slit lamp examination reveals no signs of inflammation and patients respond well with steroid eye drops within a week of treatment. This syndrome, of unknown aetiology, is significantly decreased after surgeons began using lower energies. For example, when raster energy settings are reduced by an average of 24%, the occurrence of the syndrome goes down. The same thing is noted when side-cut energy setting is reduced by 33%. Carrasquillo KG et al also observed two serious complications i.e. corneal neovascularization and fungal infection (*Fusarium* sp.) in the IntraLase treatment group during the follow-up period in the evaluation of efficacy of Intacts to treat keratoconus and post-LASIK.[9] [Level 8] Given the delayed onset of the problems in both patients in the absence of prior difficulties, it was unclear whether the occurrences of these events were related to the method of channel creation.

The most important intra-operative complications with corneal flap cut are perforation of the flap (button hole), incomplete flap formation, complete cut of the flap (free cap) and irregular and thin flap. At morphological level, Bertrand Sonigo et al assessed and compared corneal modifications induced by femtosecond laser and mechanical

microkeratome for LASIK. [10] [Level 7] In this case-control study, all Heidelberg Retina Tomograph II images were analyzed by three examiners (plus two additional examiners who did it in a masked manner). Morphologic similarities between interfaces were obtained by both techniques, probably because same excimer laser performed the photoablation. But then, IntraLase flap margin showed greater fibrotic scarring than the one induced by mechanical microtome or in other words, stronger flap adhesion. As flap edge created with laser can be deeply cut or irregular, re-epithelialization may take more time and more inflammatory cells may infiltrate in the flap surface than with a mechanical microtome.[11] [Level 9] Femtosecond lasers are able to make stronger flaps that are more resistant to trauma and reduce the incidence of flap dislocation An animal study showed that femosecond laser produced greater corneal stromal inflammation than mechanical microtome without any increase in apoptosis early postoperatively and stronger flap adhesion late postoperatively.[11] [Level 9]

Other issues that have plagued microtome technology e.g. epithelial defects, epithelial sloughing, incomplete flaps, irregular flaps and buttonhole flaps are exceptionally rare with the femtosecond technology.[3]

5.2 Effectiveness

5.2.1 Myopia ± astigmatism or nystagmus

The low amount of energy imparted via this femtosecond laser to the tissue minimizes collateral tissue damage in theory. Two RCCT studies compared visual outcome between surgeries using femtosecond laser (bladeless) and mechanical microtome on fellow eyes of myopic patients. The first study was conducted on patients attending refractive surgery clinic and it was concluded that method of flap creation did not affect visual outcomes within six months after LASIK.[12] [Level 3] In other words, although corneal backscatter (haze) was significantly 6% higher after bladeless LASIK compared to LASIK using the other method (p=0.007), patients did not perceive a difference in vision. While in the second study, induced aberrations with IntraLase (femtosecond) and Hansatome (mechanical) flap creation among patients with myopia or myopic astigmatism who were eligible for LASIK were compared.[13] [Level 3] Statistically significant changes in defocus

wavefront aberrations after Hansatome (p=0.004) and IntraLase (p=0.008) flap creation were noted. In fact, standard refractive outcomes were found to be similar in both groups. From these two studies, the new IntraLase femtosecond laser had shown that it was could produce comparable results with the more established mechanical microtome.

Many myopic patients have concomitant astigmatism. Simply reducing the spherical component of their refractive error may not produce a significant improvement in visual acuity. The refractive outcomes of the surgery are relatively unpredicatable and dependent on the skill of the surgeon.[14 Level 8] In view of this, Young In Choi et al had demonstrated that excimer laser photorefractive keratectomy with an expanding slit appeared to have a significant effect for correction of astigmatism. This was based on surgically induced refractive change (SIRC) and effect of cylindrical ablation outcomes. The finding was also consistent with a study where accuracy of astigmatism correction was better with the IntraLase femtosecond than with other devices when the predictability (variance) was noted significantly better with it.[5 Level 8] Another case series found that for correction of high myopia and myopic astigmatism, LASIK resulted in less postoperative pain and relatively little subepithelial haze compared with high myopic photorefractive keratectomy.[15 Level 8]

In laser refractive surgery, the stability of the eyes while creating the corneal flap or fixating at a target during the ablation phase is crucial to obtain satisfactory results.[16 Level8] Nystagmus is considered to be a relative contraindication for laser refractive surgery, mainly because of the patient's inability to fixate. This may cause irregular flaps or eccentric ablation which can later influence visual outcome. In a study on LASIK in myopic patients with congenital nystagmus using either IntraLase femtosecond laser or Hansatome to create corneal flaps, not only refractive errors were corrected but there was no decentration or loss of BCVA greater than 1 line.[16 Level 8] It was concluded that Laser refractive surgery may be safely and accurately performed using either both technique and active tracking system with or without mechanical fixation on patients with myopia and congenital nystagmus.

5.2.2. Corneal transplant

To eliminate the difficult dissection of the pocket in the recipient cornea and to create a smoother surface on the recipient cornea in corneal transplant, stripping of Descement's membrane was introduced. In a case report of 2006, Yanny Y.Y. Cheng et al. described the first patient with pseudophakic bullous keratoplasty treated with femtosecond-laser–assisted endothelial keratoplasty.[17] [Level 9] At 4 months post-surgery follow-up, the posterior corneal disk was clear and the induced astigmatism was 2.1 Diopters which demonstrated a functional corneal endothelial layer and rapid visual recovery to an expected postoperative visual acuity of 20/50. A significant advantage of the use of the femtosecond laser in deep lamellar endothelial keratoplasty (DSEK) is that the laser preparation of the donor tissue can be performed in an automated and standardized fashion, which reduces the technical difficulties involved in manual dissection of a posterior corneal disk. It was concluded that femtosecond laser offered a new surgical approach for minimally invasive endothelial keratoplasty in corneal endothelial disorders.

5.2.3 Keratoplasty

Excimer laser-assisted anterior lamellar keratoplasty could present as a different modality for the treatment of keratoconus, post-LASIK corneal problems and other corneal stromal opacities. This was demonstrated in a study in Turkey in 2006 where all patients gained 2 lines or more of BSCVA and there were statistically significant changes in mean corneal thickness and simulated keratometric cylinder ($p<0.05$) pre- and post-operatively.[18] [Level 8] For that matter, the surgery was safer than PKP and easier than other lamellar keratoplasty techniques. However, further studies with more patients and longer follow-up was recommended to determine the role of this promising technique. Similar finding was reported by Mike P. Holzer et al. when he mentioned that PKP can be performed with the Femtec femtosecond laser safely and accurately.[19] [Level 8] The postoperative outcome was found to be uneventful.

To assess the impact of non-mechanical trephination on the graft endothelium and thickness after penetrating keratoplasty (PKP), Berthold Seitz et al. studied 179 eyes of 179 patients.[20] [Level 2] Excimer laser trephination from the epithelial side using an artificial

anterior chamber in donors seems to have no disadvantages concerning the graft endothelium after PKP. In fact, endothelial cell loss was not increased in eyes with Fuchs' dystrophy compared with keratoconus or after triple procedures compared with PKP only. In a laboratory study to compare different techniques for predissection of human anterior and posterior lamellar corneal grafts for eye bank storage, centralized predissection by either microkeratome or femtosecond laser techniques resulted in viable grafts without significant endothelial cell loss 2 days later (provided cold storage and shipping by airmail were taken care of).[21 Level 9]

5.2.4 Keratoconus

Keratoconus, non-inflammatory but progressive ectatic disease of the cornea, is principally treated with rigid gas-permeable (GP) contact lenses in most cases. However, some patients become intolerant to it and thus surgery, usually PKP becomes necessary. Currently, two types of intrastromal corneal ring segments are available for ophthalmic surgery.[22 Level 8] Intacs used for the treatment of mild to moderate keratonus and post-LASIK keratectasia by using either traditional mechanical dissection or femtosecond laser were studied.[9 Level 8] The authors did not find statistically significant difference in outcomes between both techniques in Intacs channel creation. Due to limitations of the study, although the statistical power was adequate to detect changes in clinical parameters as a result of the surgery, it was not sufficient enough to conclusively show such differences between surgical techniques.

In another related study but using other type of intrastromal corneal ring segments, Shabayek MH and Alió JL reported that KERARING implantation (refer **Figure 4**) with femtosecond laser was effective for correcting keratoconus with reduction in corneal HOA in eyes with coma aberration more than 3.0 µm.[22 Level 8] Although the authors claimed that there were no surgical complications / excellent corneal tolerance in the operated eyes, unpredictable corneal biochemical response was noted in the study too. Further studies to compare and clarify the differences between manual traditional dissection and femtosecond laser dissection were suggested. Aylin Ertan et al. revealed the longest follow-up case series on the use of femtosecond laser for Intacs implantation

to correct keratoconus.[23 Level 8] The study involved 118 consecutive eyes of 69 patients. Improved UCVA and BCVA, decreased mean keratometry and refractive spherical equivalent were statistically significant by 1 year follow-up ($p<0.05$). In conclusion, intact implantation with femtosecond laser was said to be safe and effective (minimally invasive and with fewer complications for treatment of keratoconus).

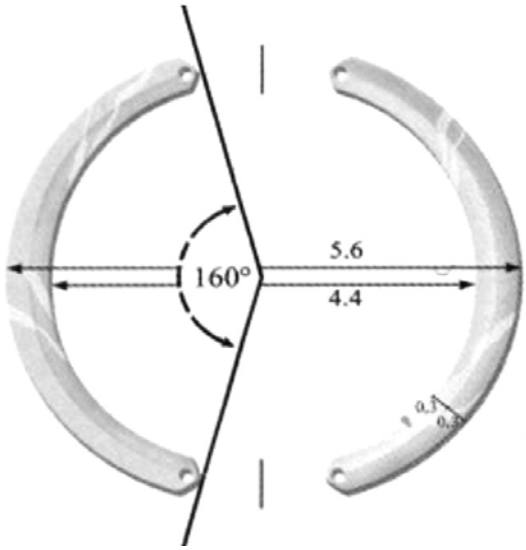

Figure 4. Diagram showing the design and the diameter of intrastromal corneal ring segments[22 Level 8]

5.2.5 Corneal erosion

In cases of recurrent corneal erosion syndrome (RCES) refractory to conservative measures, other options for treatment include phototherapeutic keratectomy (PTK). A retrospective case series studied the long-term sequelae of PTK for the treatment of the condition of various aetiologies.[24 Level 8] Using Kaplan-Meier survival analysis, 25% of eyes had a recurrence by 3 months and 36% had it by 9 months. No serious adverse effects were reported. Thus, long-term data suggested that most patients treated with PTK do not develop recurrences, and side effects from PTK were minimal. In another study on corneal scarring (based on abstract), pre-PTK tear function parameters and tear film lipid layer interferometry improved gradually and significantly within six months PTK.[25 Level 6] It was concluded then that PTK was an effective means of treating corneal scars and attaining visual improvement, even in cases with deeper corneal involvement. This may obviate the need for corneal transplantation.

5.3 Cost-effectiveness

There was no literature retrieved that discussed specifically on cost-effectiveness of laser-assisted corneal ophthalmic surgery. The cost of the femtosecond laser is considerable, but improving patient outcomes and surgical efficiency is paramount in the medical services.[2]

6. CONCLUSION

There are sufficient evidences to support the safety and effectiveness in using laser-assisted procedures in corneal ophthalmic surgery. In term of safety, the laser-assisted corneal surgery was reportedly to be in favour with regard to problems of loose epithelium / epithelial defects, post-LASIK ectasia and cataract formation. For Transient Light Sensitivity Syndrome, technical advances that reduced pulse energies appear to decrease its incidence. Laser-assisted corneal surgery was also found to be effective in creating precise corneal incisions (e.g. in flap creation in LASIK) and in conditions with limited optical clarity. It was also an efficient alternative modality in the treatment of many ophthalmic disorders (e.g. in keratoconus) with little complication. In the case of corneal scar, corneal transplantation may be avoided altogether.

7. RECOMMENDATION

Based on the above review, laser-assisted ophthalmic surgery has proven to be a safe and efficient mode of treatment in many pathological corneal conditions. Although such laser-assisted surgery is more costly than the conventional methods, studies ranges from RCCT to animal study have supported the wider use of such procedures which will benefit the patients eventually. Having said that, some studies has recommended larger number of study subjects and longer period of follow-up to strengthen the evidences obtained so far.

8. REFERENCES

[1] Alan Sugar. Ultrafast (femtosecond) laser refractive surgery. Curr Opin Ophthalmol 2002; Vol.13: 246-249

[2] Shahzad I.Mian and Roni M.Shtein. Femtosecond laser-assisted corneal surgery. Curr Opin Ophthalmol 2007; Vol.18: 295-299

[3] Karl Stonecipher, Teresa S.Ignacio, Megan Stonecipher. Advances in refractive surgery: microtome and femtosecond laser flap creation in relation to safety, efficacy, predictability, and biochemical stability. Curr Opin Ophthalmol 2006; Vol.17: 368-372

[4] Excimer laser. (Internet communication, 28 September 2007 at http://en.wikipedia.org/wiki/Excimer_laser)

[5] Guy M. Kezirian, Karl G. Stonecipher. Comparison of the IntraLase femtosecond laser and mechanical keratomes for laser in situ keratomileusis. J Cataract Refract Surg. Apr 2004; Vol.30(4): 804-811

[6] Ioannis G.Pallikaris, George D.Kymionis, Nikolaos I.Astyrakakis. Corneal ectasia induced by laser in situ keratomileusis. J Cataract Refract Surg Nov 2001; Vol.27: 1796-1802

[7] Ashley Behrens et al. Lens opacities after nonmechanical versus mechanical corneal trephination for keratoplasty in keratoconus. J Cataract Refract Surg November 2000; Vol. 26: 1605-1611

[8] Karl G. Stonecipher et al. Transient light sensitivity after femtosecond laser flap creation: Clinical findings and management. J Cataract Refract Surg Jan 2006; Vol. 32 : 91 - 94

[9] Carrasquillo KG, Rand J, Talamo JH. Intacs for keratoconus and post-LASIK ectasia: mechanical versus femtosecond laser-assisted channel creation. Cornea 2007 Sep; Vol.26 (8): 956-62.

[10] Bertrand Sonigo et al. In Vivo Corneal Confocal Microscopy Comparison of IntraLase Fentosecond & Mechanical Microkeratome for Laser in Situ Keratomileusis. *IOVS* July 2006; Vol.47.No.7: 2803-2811

[11] Jae Yong Kim et al. A Femtosecond Laser creates a stronger flap than a Mechanical Microtome. *IOVS* February 2006; Vol.47.No.2: 599-604.

[12] Sanjay V.Patel et al. Femtosecond laser versus Mechanical Microkeratome for LASIK. Ophthalmology. August 2007; Vol.114. No.8: 1482-1487

[13] Dan B. Tran et al. Randomized prospective clinical study comparing induced aberrations with IntraLase and Hansatome flap creation in fellow eyes. J Cataract Refract Surg January 2005; Vol. 31: 97-105.

[14] Young In Choi, Hong Kee Min, Pil Mok Hyun. Excimer Laser Photorefractive Keratectomy for Astigmatism. Kor.J.Ophthalmol 1993 Jun; Vol. 007(01): 20-24.

[15] P I Condon et al. Laser intrastromal keratomileusis for high myopia and myopic astigmatism. *Br J Ophthalmol* 1997 March; Vol.81**:**199-206.

[16] Mahler et al. Laser in situ keratomileusis in myopic patients with congenital nystagmus. J Cataract Surg. 2006 Mar; Vol. 32 (3): 464-7

[17] Yanny Y.Y. Cheng, Elisabeth Pels, Rudy M.M.A. Nuijts. Femtosecond-laser–assisted Descemet's stripping endothelial keratoplasty. Journal of Cataract & Refractive Surgery January 2007; Vol.33, Issue 1: 152-155

[18] Kamil Bilgihan et al. Excimer laser-assisted anterior lamellar keratoplasty for keratoconus, corneal problems after laser in situ keratomileusis, and corneal stromal opacities. J Cataract Refract Surg 2006; Vol.32: 1264–1269.

[19] Mike P. Holzer, Tanja M. Rabsilber, Gerd U. Auffarth. Penetrating Keratoplasty Using Femtosecond Laser. American Journal of Ophthalmology March 2007: Vol.143, Issue 3: 524-526

[20] Berthold Seitz et al. Graft endothelium and thickness after penetrating keratoplasty, comparing mechanical and excimer laser trephination: a prospective randomised study. Graefe's Arch Clin Exp Ophthalmol (2001); Vol.239: 12–17.

[21] Olan Suwan-apichon et al. Microkeratome versus Femtosecond laser predissection of corneal grafts for anterior and posterior lamellar keratoplasty. Cornea September 2006; Vol. 25.No.8: 966-968.

[22] Shabayek MH, Alió JL. Intrastromal corneal ring segment implantation by femtosecond laser for keratoconus correction. Ophthalmology 2007 Sep; Vol.114 (9): 1643-52.

[23] Aylin Ertan, Gunhal Kamburoglu, Mehmet Bahadir. Intacts insertion with the femtosecond laser for the management of keratoconus One-year results. J Cataract Refract Surg Dec 26; Vol.32:2039–2042.

[24] Baryla, J, Pan, Y I, Hodge, W G. Long-Term Efficacy of Phototherapeutic Keratectomy on Recurrent Corneal Erosion Syndrome. Cornea 2006 Dec; Vol.25 (10): 1150-2.

[25] Dogru M et al. Visual and tear function improvement after superficial phototherapeutic keratectomy (PTK) for mid-stromal corneal scarring. Eye. 2000 Oct; Vol.14 Pt 5: 779-84.

1. APPENDICES

9.1 Appendix 1 - Level of Evidence Table

Level	Strength of evidence	Study design
1	**Good**	**Meta-analysis of RCT, Systematic review**
2	**Good**	**Large sample RCT**
3	**Good to fair**	**Small sample RCT**
4		**Non randomized controlled prospective trial**
5	**Fair**	**Non randomized controlled prospective trial with historical control**
6	**Fair**	**Cohort studies**
7	**Fair**	**Case-control studies**
8	**Poor**	**Non controlled clinical series, descriptive studies multicentre**
9	**Poor**	**Expert committees, consensus, case reports, anecdotes, laboratory study, animal study**

Source: Adapted from Catalonian Agency for Health Technology Assessment (CAHTA), Spain

9.2 Appendix 2 - Abbreviations

LASIK – Laser in situ keratomileusis

ALK – Anterior lamellar keratopalsty

PLK – Posterior lamellar keratoplasty

UCVA – Uncorrected visual acuity

BSCVA – Best spectacle corrected visual acuity

RCCT – Randomized Controlled Clinical Trial

PKP – Penetrating keratoplasty

PTK – Phototherapeutic keratectomy

POD – Post-operation day

NMT – Non-mechanical trephination

MT – Mechanical trephination

FS – Femtosecond

MM – Mechanical microtome

HOA – Higher Order Wavefront Aberration

LOA – Lower Order Wavefront Aberration

PRK – Photorefractive keratectomy

PK – Penetrating keratoplasty

D – Diopter