

CLINICAL PRACTICE GUIDELINES

December 2005

MOH/PAK/ 103.05(GU)

RETINOPATHY OF PREMATURITY



MINISTRY OF HEALTH MALAYSIA



ACADEMY OF MEDICINE MALAYSIA

Statement of Intent

This clinical practice guideline is based on the best available evidence at the time of development. All health care providers are responsible for the management of their patients based on the clinical picture. The management depends on the options available locally.

Review of Guidelines

This guideline was issued in 2005 and will be reviewed in 2007 if new evidence becomes available.

Health Technology Assessment Unit
Medical Development Division
Ministry of Health Malaysia
Level 4, Block E1, Precinct 1
Government Office Complex
62590, Putrajaya

Available on the following website: <http://www.moh.gov.my>
<http://www.acadmed.org.my>

GUIDELINES DEVELOPMENT AND OBJECTIVES

Guidelines Development

The work group for the development of the guidelines comprised of ophthalmologists from the Ministry of Health and Ministry of Education faculties of the government and the private sector. These guidelines are adapted from the guidelines on retinopathy of prematurity from the Royal College of Ophthalmologists and British Association of Perinatal Medicine. A systematic review of current evidence is carried out and the evidence is ranked. The ranking of evidence is based on a modified version of the Catalonia Agency for Health Technology Assessment and Research (CAHTAR) Spain (Appendix 1). The draft of guidelines is posted on the websites of Ministry of Health Malaysia and Academy of Medicine Malaysia for comments and feedback. These guidelines have also been presented to the Technical Advisory Committee for Clinical Practice Guidelines and Health Technology Assessment and Clinical Practice Guidelines Council, Ministry of Health Malaysia for review and approval.

Objectives

The aim of these guidelines is to help the health care providers in clinical decision-making by providing evidence-based information on retinopathy of prematurity.

Clinical Questions

The clinical questions for these guidelines are:

- i. Who should be screened for ROP?
- ii. How should these babies be screened?
- iii. How should patients with ROP be managed?
- iv. What should be the follow up of these patients?

Target Population

These guidelines are for the management of infants with the risk of developing retinopathy of prematurity and those with the established disease.

Target Group

These guidelines are meant for all health care providers.

GUIDELINES COMMITTEE

1. Dr Joseph Alagaratnam (Chairman)
Consultant Ophthalmologist
Hospital Kuala Lumpur
2. Dr Karunakar TVN
Consultant Ophthalmologist
Hospital Kuala Lumpur
3. Dr Ronald Arun Das
Consultant Ophthalmologist
Hospital Selayang
4. Dr Choong Yee Fong
Consultant Ophthalmologist
Hospital Selayang
5. Dr Nor Higrayati Ahmad Kesah
Consultant Ophthalmologist
Kuala Terengganu Hospital
6. Dr Choo May May
Consultant Ophthalmologist
University Malaya Medical Centre
7. Dr Suraiya Mohd Shafie
Consultant Ophthalmologist
Hospital Universiti Kebangsaan Malaysia
8. Dr Rozita Ahmad
Consultant Ophthalmologist
Ampang Puteri Specialists Hospital

External reviewer

Dato Dr Lim Nyok Ling
Consultant Pediatrician,
Selayang Hospital

Project Coordinators

1. Ms Sin Lian Thye
Nursing Officer
Health Technology Assessment Unit
Ministry of Health Malaysia
2. Dr Premila Paranchothy
Assistant Director
Health Technology Assessment Unit
Ministry of Health Malaysia

Reviewed and edited by

Dr S Sivalal
Head, Health Technology Assessment Unit
Deputy Director, Medical Development Division
Ministry of Health Malaysia

TABLE OF CONTENTS

| | | |
|---|--|----|
| | GUIDELINES DEVELOPMENT AND OBJECTIVES | i |
| | GUIDELINES COMMITTEE | ii |
| 1 | INTRODUCTION | 1 |
| 2 | CLASSIFICATION OF ROP | 1 |
| 3 | RISK FACTORS | 1 |
| | 3.1 Birth weight and gestational age | 1 |
| | 3.2 Oxygen Use | 1 |
| | 3.3 Light Exposure | 2 |
| | 3.4 Other Risk Factors | 2 |
| 4 | INDICATION FOR TREATMENT | 2 |
| 5 | TREATMENT | 3 |
| | 5.1 Timing | 3 |
| | 5.2 Type of Surgery | 3 |
| | 5.2.1 <i>Laser therapy</i> | 3 |
| | Complications | 3 |
| | 5.2.2 <i>Cryotherapy</i> | 3 |
| | Complications | 3 |
| | 5.2.3 <i>Treatment of advanced disease</i> | 3 |
| | 5.2.4 <i>Vitreoretinal surgery</i> | 3 |
| | 5.2.5 <i>Disorganised anterior segment</i> | 3 |
| 6 | COMPLICATION | 4 |
| 7 | SCREENING | 4 |
| | 7.1 When to screen | 4 |
| | 7.2 Discontinue screening | 4 |
| | 7.3 Personnel to carry out screening | 5 |
| | 7.4 Screening method | 5 |
| 8 | COUNSELLING | 5 |
| 9 | FOLLOW UP | 6 |
| | 9.1 Post screening follow-up | 6 |
| | 9.2 Follow-up of children treated for ROP | 6 |
| | 9.3 Follow-up of patients with threshold ROP | 6 |
| | 9.4 Follow-up of patients with complications of ROP | 6 |
| | ALGORITHM OF ROP | 7 |
| | ALGORITHM OF TREATMENT OF ROP | 8 |
| | REFERENCES | 9 |
| | Appendix 1 -Levels Of Evidence Scale | 14 |
| | Appendix 2 - Retinopathy of Prematurity Classification | 15 |
| | Appendix 3 - Preparation Procedure for Treatment of Retinopathy of Prematurity | 18 |
| | Appendix 4 - Cryotherapy Procedure | 21 |
| | Appendix 5 – General Information for Parents | 22 |

1 Introduction

Retinopathy of prematurity (ROP) is a retinal disorder of low birth weight premature infants. It can be mild with no visual defects, or it may become aggressive with new vessel formation (neovascularisation) and progress to retinal detachment and blindness.¹ The stimulus for the abnormal growth of blood vessels comes from the peripheral immature retina. Early detection and effective management of this condition can prevent blindness.

2. Classification of ROP

ROP is categorised based on the severity of the disease into stages (0-5), location of the disease into 3 zones (1-3), extent of the disease based on clock hours (1-12) and the presence of plus disease.¹ (Refer Appendix 2 for detailed classification of ROP).

3. Risk factors

3.1 Birth weight and gestational age

Infants with very low birth weight are at significantly higher risk of developing severe ROP that requires treatment. Similarly, the severity of ROP is inversely proportional to gestational age. Present evidence shows that low birth weight and gestational age are the most predictive risk factors for the development of ROP ^{2-3 level 1; 4- 14 level 8; 15 level 9; 16 level 6}.

3.2 Oxygen Use

Oxygen therapy has been previously implicated in the aetiology of ROP ^{17 level 8; 18 level 6}. The use of supplemental oxygen neither caused progression of pre-threshold ROP nor significantly reduced the number of infants requiring peripheral ablative therapy^{19 level 4}. Recent evidence suggests that repeated hypoxic and hyperoxic episodes may be an important factor in the pathogenesis of ROP ^{20 level 5}. Strict management of oxygen delivery without fluctuations and monitoring may be associated with decreased occurrence of ROP ^{20 level 5}. Although the exact relationship between oxygen therapy and ROP is currently not well established, oxygen therapy seemed to play an important role in the pathogenesis of ROP.

3.3 Light Exposure

There is no evidence that light exposure is a risk factor in the development of ROP, since reduction in ambient light exposure has not reduced the incidence of ROP in high risks infants ^{21 level 4}.

3.4 Other Risk Factors

The other risk factors that have been implicated in the development of ROP include use of, glucocorticoids ^{23 level 8}, surfactant ^{24 level 8},

indomethacin^{25 level 6}, xanthine^{26 level 6}, and dopamine^{27 level 8}. In addition, ROP has also been associated with intra-ventricular haemorrhage^{28 level 8}, ante-natal blood loss requiring blood transfusions and surgery under general anaesthesia^{29 level 9}, sepsis^{30 level 8; 31 level 8; 32 level 6; 33 level 7}, candidemia^{34 level 6; 35 level 6}, carbon dioxide tension^{36 level 8}, raised serum bilirubin levels^{39 level 8}, and assisted conception^{40 level 8; 41 level 6}.

However, there is insufficient evidence to determine the degree of importance of these risk factors in contributing to the pathogenesis of ROP.

4. Indications of treatment

Ablative treatment of avascular retina should be considered in patients with the following features:

- **Threshold disease of ROP**^{3;49;58;59;60;61;62}
Defined as having all the following features
 - Stage 3 ROP in zone 1, or zone 2
 - Involving 5 or more contiguous clock hours; or 8 or more cumulative clock hours **and**
 - the presence of plus disease

With threshold disease there is a 50% predicted risk of blindness.

- **High risk pre-threshold disease of ROP**^{2 level 2; 54; 55 level 8}
Defined as **any** of the following
 - Zone 1, any stage ROP with plus disease
 - Zone 1, stage 3 ROP without plus disease **or**
 - Zone 2, stage 2 or 3 ROP with plus disease

The early treatment of high-risk pre-threshold ROP significantly reduces unfavorable outcome.^{2 level 2}

5. Treatment

The principle of treatment is to remove the stimulus for growth of new blood vessels by ablating the peripheral avascular retina. This will in turn reduce the incidence of retinal detachment and consequent blindness.

5.1 Timing

When indicated, treatment should be carried out as soon as possible, ideally within 2-3 days of the diagnosis. The rationale is that the disease can advance rapidly and any delay in treatment will reduce the chances of success.

5.2 Type of treatment

5.2.1 Laser therapy

Laser therapy is the procedure of choice, being less invasive, less traumatic to the eye and causes less discomfort to the infant^{53 level 4; 56 level 5}. Laser is also simpler to apply in treating posteriorly located disease. Both Argon green and Diode red wavelengths laser can be delivered through an indirect ophthalmoscope. Laser burns should be applied on the peripheral avascular retina. Ideally laser applications should be spaced one half burn-width apart^{57 level 8; 56 level 5}. (For details of preparation of patient for treatment please refer to Appendix 3).

Complications of laser therapy

Laser treatment may cause burns in cornea and iris. Other complications include cataract, and retinal and vitreous haemorrhage^{57 level 8}.

5.2.2 Cryotherapy

Cryotherapy significantly improves the outcome of severe ROP^{58 - 62 level 5}. This has been largely superseded by laser photocoagulation due to its higher incidence of treatment related complications.

(The details of cryotherapy treatment are provided in Appendix 4)

Complications of cryotherapy

Cryotherapy can result in ocular complications like eyelid edema, laceration of the conjunctiva, and pre-retinal and vitreous haemorrhage as well as systemic complications like bradycardia, cyanosis and respiratory depression⁶³.

5.2.3 Treatment of advanced disease

Neither cryotherapy nor laser photocoagulation is successful in all cases of advanced disease. Despite meticulous management there may be serious sequelae.

5.2.4 Vitreoretinal surgery

Scleral buckling is advocated for stage 4B and stage 5 ROP^{64 level 8}. Lens sparing vitreous surgery can also be carried out, preferably at 38 to 42 weeks of postmenstrual age^{65 level 8}. Patients with advanced disease or severe ROP should be referred to a tertiary centre for further management.

5.2.5 Disorganised anterior segment

Lens aspiration should be considered in children with advanced cicatricial ROP with shallow or flat anterior chamber. It is done to

prevent secondary glaucoma which may develop due to the anterior displacement of iris-lens diaphragm.

6. Complications of ROP

- Myopia occurs in about 80% of infants with ROP ^{47 level 6}.
- Strabismus and amblyopia are also common residual findings. The prevalence of strabismus ranges from 23% to 47% in infants with ROP and found to be 20% in a regional study ^{47 level 6; 48 level 8}.
- Retinal detachment has been seen in 22% patients ^{49 level 2}. Retinal detachment can occur as early as 6 months up to 31 years from the time of diagnosis, with a mean age of 13 years in regressed ROP patients ^{50 level 8}.
- Retinal detachment may even occur in sub-threshold ROP ^{51 level 8}.
- Acute angle closure glaucoma can be seen in cicatricial ROP. ^{52 level 8}.

7. Screening

7.1 Whom to screen

Screening should be carried out for the infants with **either** of the following:

- Birth weight less than 1500 g **or**
- Gestational age less than 32 weeks **or**
- Infants with an unstable clinical course who are at high risk (as determined by the neonatologist or paediatrician)

7.2 When to screen

The first examination should be done 4 to 6 weeks after birth since very early examination may have no value ^{3 level 1; 7 level 9}.

Screening of all infants at risk of developing ROP should be continued regularly until:

- Retina is completely vascularised
- ROP has fully regressed and there are no signs of risk for visual loss
- ROP has progressed to a level of severity where treatment is indicated.

The following are the recommended follow up intervals for the infants at risk. ^{2;3;49;58;59;60;61;62}

No signs of ROP

Infants at risk should be screened at 2-3 week intervals until the retina is fully vascularised.

If ROP is present

Zone 1

Zone 1, stage 1, 2 or 3 ROP without plus disease should be screened at least weekly because there is a high risk of disease progression.

Zone 2

Zone 2 stage 1 ROP should be screened 2 weekly

Zone 2 stage 2 ROP without plus should be screened 1-2 weekly

Zone 2 stage 3 ROP without plus should be screened at least weekly.

7.3 Personnel to carry out screening

Medical personnel sufficiently trained in ROP screening should perform the examination. Preferably the team should comprise an experienced ophthalmologist, resident and a nurse.

7.4 Screening method

Screening can be carried out using the following instruments:

- Indirect ophthalmoscope with a 20, 28 or 30 D lens (28D or 30D lens are usually preferred as they allow easier viewing of the peripheral retina).
- Eye speculum
- Scleral indenter

The RetCam examination is not sufficiently sensitive to be a substitute for indirect ophthalmoscopic examination ^{45 level 4}.

Nesting (wrapping) of infants can significantly reduce the stress during screening procedure ^{46 level 7}.

8. Counselling

Counselling of the parents is essential depending on the severity of the disease ^{67 level 9}.

- **Parents of all babies at risk** - written general information should be provided (see Appendix 5 for details of general information for parents).
- **Parents of infants with severe ROP** - the ophthalmologist should personally discuss about the disease and availability of management with the parents.

- **Parents of infants with advanced cicatricial ROP and with visual impairment** – It is important to ensure that children with visual impairment have access to all services, registration with relevant associations of the blind and vocational guidance centers.

9. Follow up

9.1 Post screening

- Assessment of vision should be carried out in all pre-term infants throughout the first year of life to detect associated disorders like neurological abnormalities and amblyopia.
- Periodic monitoring of visual acuity is also carried out since severe ROP may be associated with impaired visual development.

9.2 Children treated for ROP

Post treatment follow- up should be carried out for all infants till they reach pre-school years, to monitor the development of vision, refractive status and strabismus.

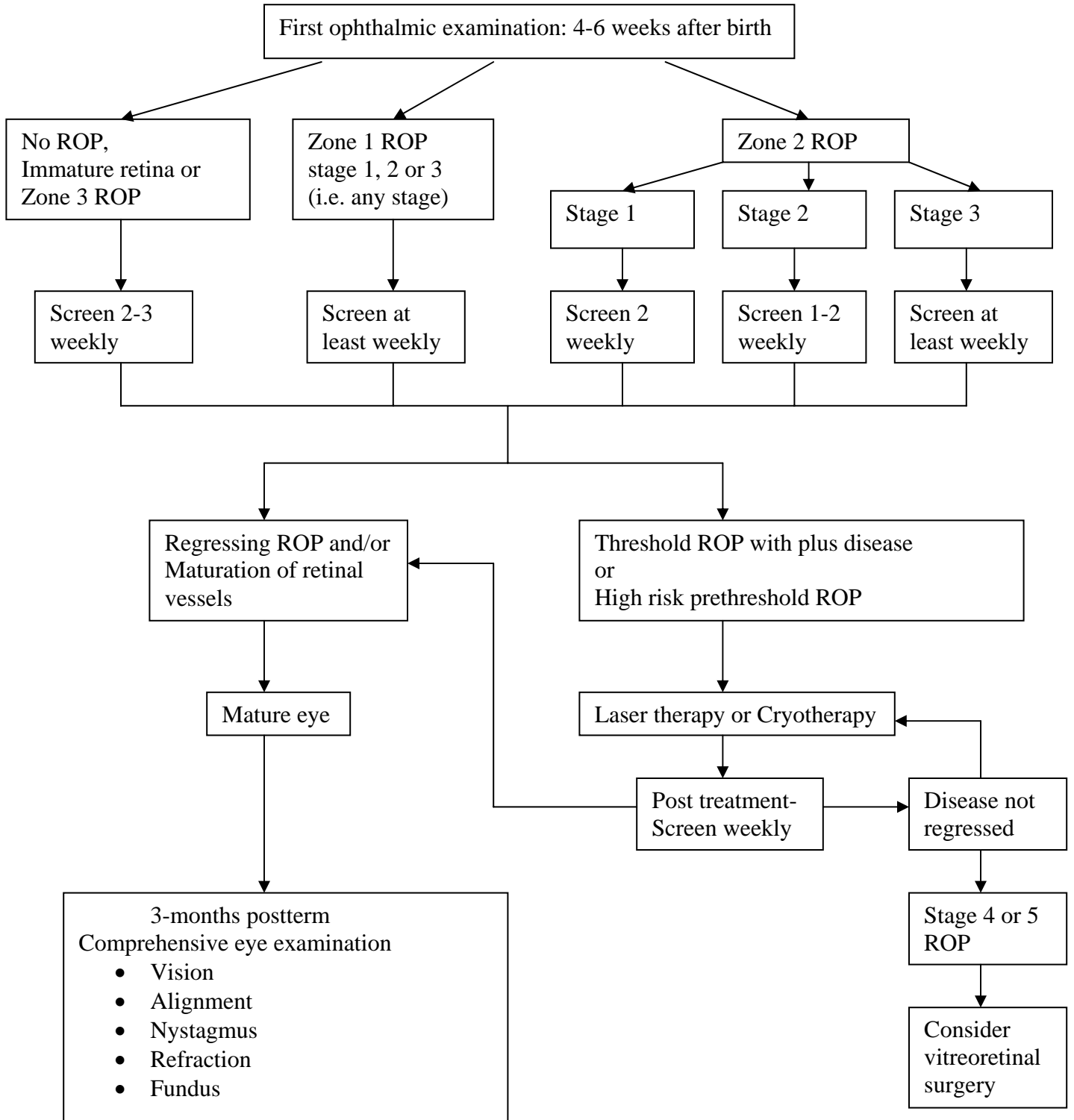
9.3 Children with threshold ROP

- Follow - up examinations should be tailored individually.
- If adequate laser/cryotherapy treatment has been given, and the disease has fully regressed, a follow-up examination should be carried out at 3 months.
- Cycloplegic refraction should be performed at 6 months.
- Follow-up should be annually. Sometimes more frequent follow up is necessary if indicated.

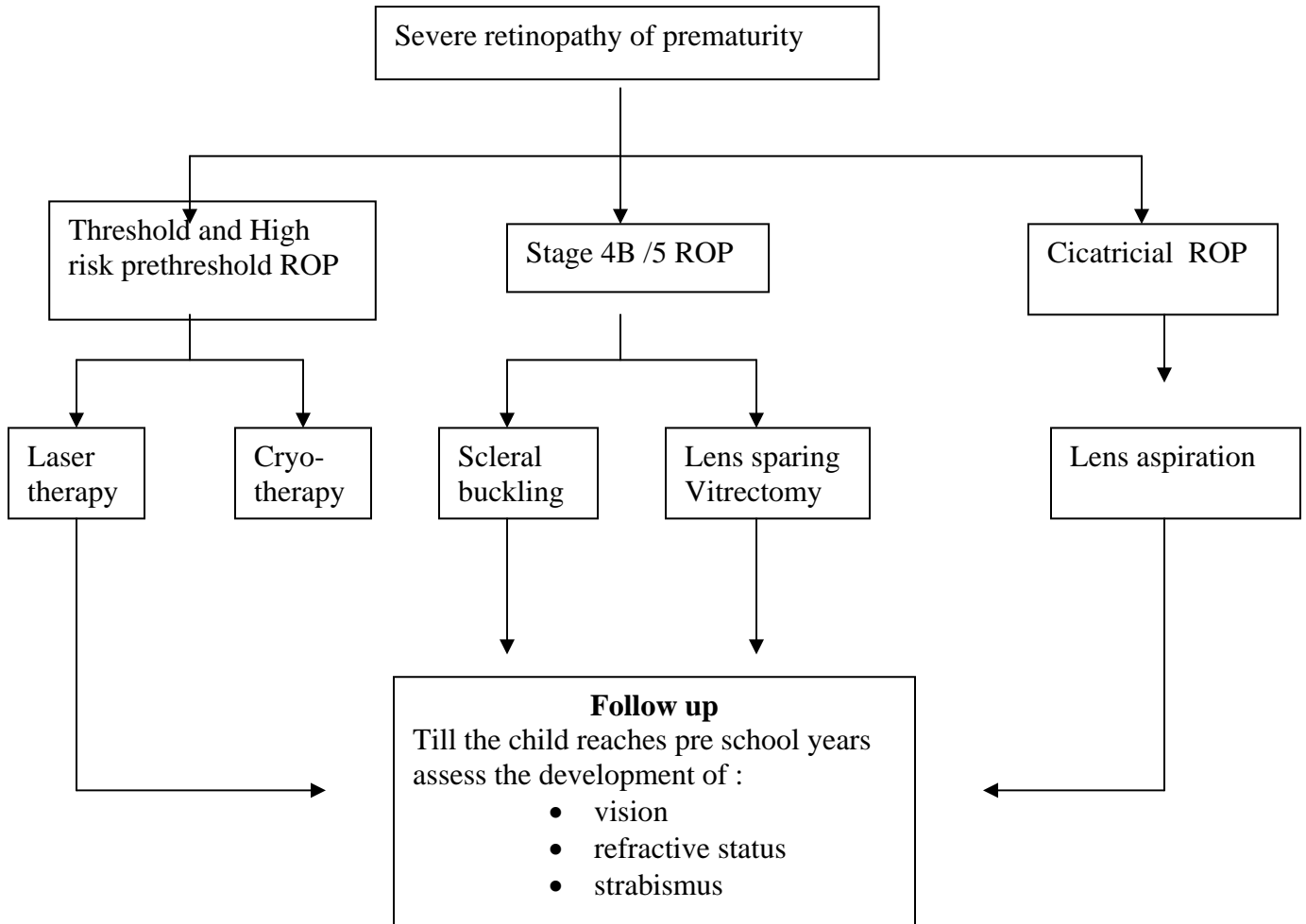
9.4 Children with complications of ROP

Ophthalmologist must ensure that the child gains early access to the services for the visually impaired. The social and educational services provide much needed support to these children.

**ALGORITHM OF SCREENING AND TREATMENT FOR
RETINOPATHY OF PREMATUREITY**



ALGORITHM OF TREATMENT FOR RETINOPATHY OF PREMATUREITY



REFERENCES

- 1 Gerontis CC (2004) *Retinopathy of prematurity*, e-medicine Sept 22.
- 2 Early Treatment for Retinopathy Of Prematurity Cooperative, Group (2003). Revised indications for the treatment of retinopathy of prematurity: results of the early treatment for retinopathy of prematurity randomized trial. *Arch Ophthalmol* 121(12), pp 1684-94.
- 3 Reynolds JD, Dobson V, et al. (2002). Evidence-based screening criteria for retinopathy of prematurity: natural history data from the CRYO-ROP and LIGHT-ROP studies. *Arch Ophthalmol*, 120(11), pp 1470-6.
- 4 Trinavarat A, Atchaneeyasakul LO et al. (2004). Applicability of American and British criteria for screening of the retinopathy of prematurity in Thailand. *Jpn J Ophthalmol*, 48(1), pp 50-3.
- 5 Al-Amro SA, Al-Kharfi TM, et al. (2003). Retinopathy of prematurity at a University Hospital in Riyadh, Saudi Arabia. *Saudi Med J*, 24(7), pp 720-4.
- 6 Hutchinson AK, O'Neil JW, et al. (2003). Retinopathy of prematurity in infants with birth weights greater than 1250 grams. *J Aapos*, 7(3), pp 190-4
- 7 Lin WH, Chen SJ, et al. (2003). Retinopathy of prematurity: optimal timing of the initial check and progression after discharge. *Acta Paediatr Taiwan*, 44(2), pp 84-8.
- 8 Phan, MH, Nguyen PN, et al. (2003) Incidence and severity of retinopathy of prematurity in Vietnam, a developing middle-income country. *J Pediatr Ophthalmol Strabismus*, 40(4), pp 208-12.
- 9 Coats DK, Paysse EA, et al. (2000). Threshold retinopathy of prematurity in neonates less than 25 weeks' estimated gestational age. *J Aapos* 4(3), pp 183-5.
- 10 Andruscavage L & Weissgold DJ (2002). Screening for retinopathy of prematurity. *Br J Ophthalmol*, 86(10), pp 1127-30.
- 11 Chiang MC, Tang JR, et al. (2002). A proposal of screening guideline for retinopathy of prematurity in Taiwan. *Acta Paediatr Taiwan*, 43(4), pp 204-7.
- 12 Delport,SD, Swanepoel JC, et al. (2002). Incidence of retinopathy of prematurity in very-low-birth-weight infants born at Kalafong Hospital, Pretoria. *S Afr Med J*, 92(12), pp 986-90.
- 13 Larsson E & Holmstrom G (2002). Screening for retinopathy of prematurity: evaluation and modification of guidelines. *Br J Ophthalmol*, 86(12), pp 1399-402.
- 14 Chye JK, Lim CT, et al. (1999). Retinopathy of prematurity in very low birth weight infants. *Ann Acad Med Singapore*, 28(2), pp 193-8.
- 15 Clemett R & Darlow B (1999). Results of screening low-birth-weight infants for retinopathy of prematurity. *Curr Opin Ophthalmol*, 10(3), pp 155-63.
- 16 Higgins RD, Mendelsohn AL, et al. (1999). Retinopathy of prematurity: lack of association with prenatal care. *J Aapos* 3(2), pp 114-6.
- 17 Keith CG, Smith ST et al. (1981). Retrolental fibroplasia: a study of the incidence and aetiological factors, 1977-1979. *Med J Aust*, 2(11), pp 589-92.

- 18 Rekha S & Battu RR (1996). Retinopathy of prematurity: incidence and risk factors. *Indian Pediatr*, 33(12), pp 999-1003
- 19 STOP-ROP Study (2000). Supplemental Therapeutic Oxygen for Prethreshold Retinopathy of Prematurity (STOP-ROP), a randomized, controlled trial. I: primary outcomes. *Pediatrics*, 105(2), pp 295-310.
- 20 Chow LC, Wright KW, et al. (2003). Can changes in clinical practice decrease the incidence of severe retinopathy of prematurity in very low birth weight infants? *Pediatrics*, 111(2), pp 339-45.
- 21 Light -ROP (1999). The design of the multicenter study of light reduction in retinopathy of prematurity (LIGHT-ROP). *J Pediatr Ophthalmol Strabismus*, 36 (5), pp 257-63.
- 22 Brion LE. Bell, et al. (2003). Vitamin E supplementation for prevention of morbidity and mortality in preterm infants. *Cochrane Database Syst Rev* 4: CD003665
- 23 Wright K & Wright SP (1994). Lack of association of glucocorticoid therapy and retinopathy of prematurity. *Arch Pediatr Adolesc Med*, 148(8), pp 848-52.
- 24 Brunner-Di Pietro, D., E. Bossi, et al. (1995). Screening for retinopathy of prematurity after surfactant treatment, *Eur J Pediatr*, 154(9 Suppl 4), pp S90-4.
- 25 Darlow BA, Horwood LJ et al (1992). Retinopathy of prematurity: risk factor in a prospective population-based study. *Paediatric Perinat Epidemiol*, 6(1), pp 62-80
- 26 Hammer ME, Mullen PW, et al. (1986). Logistic analysis of risk factors in acute retinopathy of prematurity. *Am J Ophthalmol*, 102(1), pp 1-6
- 27 Mizoguchi, MB, Chu TG, et al. (1999). Dopamine use is an indicator for the development of threshold retinopathy of prematurity. *Br J Ophthalmol*, 83(4), pp 425-8.
- 28 Watts P, Adams GG, et al. (2000). Intraventricular haemorrhage and stage 3 retinopathy of prematurity. *Br J Ophthalmol*, 84(6), pp 596-9.
- 29 Jandek C Kellner U, et al. (1996). Retinopathy of prematurity in infants of birth weight > 2000 g after haemorrhagic shock at birth. *Br J Ophthalmol*, 80(8), pp 728-31.
- 30 Aggarwal R, Agarwal R, et al. (2002) Retinopathy of prematurity. *Indian J Pediatr*, 69(1): 83-6.
- 31 Yang, CS, Chen SJ et al. (2001). Retinopathy of prematurity: screening, incidence and risk factors analysis. *Zhonghua Yi Xue Za Zhi (Taipei)*, 64(12), pp 706 -12.
- 32 Bassiouny, MR. (1996). Risk factors associated with retinopathy of prematurity: a study from Oman. *J Trop Pediatr*, 42(6), pp 355-8
- 33 Cats BP & Tan KE. (1985). Retinopathy of prematurity: review of a four-year period. *Br J Ophthalmol*, 69(7), pp 500-3.
- 34 Karlowicz MG. Giannone PJ, et al. (2000) Does candidemia predict threshold retinopathy of prematurity in extremely low birth weight ($\leq 1000\text{ g}$) neonates? *Pediatrics*, 105(5), pp 1036-40.

- 35 Mittal M, Dhanireddy R et al. (1998). Candida sepsis and association with retinopathy of prematurity. *Pediatrics*, 101(4 Pt 1), pp 654-7
- 36 Liao SL, Lai SH, et al. (2000). Effect of carbon dioxide tension in the first three days of life on the development of retinopathy of prematurity. *Chang Gung Med J*, 23(12), pp 755 - 60
- 37 Higgins, RD, Mendelsohn AL, et al. (1998) Antenatal dexamethasone and decreased severity of retinopathy of prematurity. *Arch Ophthalmol*, 116(5), pp 601-5.
- 38 Hylander MA, Strobino DM, et al (2001). Association of human milk feedings with a reduction in retinopathy of prematurity among very low birth weight infants *J Perinatol*, 21(6), pp 356 - 62
- 39 Yeo KL., Perlman M, et al (1998). Outcomes of extremely premature infants related to their peak serum bilirubin concentrations and exposure to phototherapy. *Pediatrics*, 102(6), pp 1426 - 31
- 40 Watts P. & Adams GS (2000). In vitro fertilisation and stage 3 retinopathy of prematurity. *Eye*, 14 (Pt 3A), pp 330 - 3.
- 41 McKibbin M & Dabbs TR (1996). Assisted conception and retinopathy of prematurity. *Eye*, 10 (Pt 4), pp 476 - 8.
- 42 Fielder AR (2003). Preliminary Results of Treatment of eyes with High - Risk Prethreshold Retinopathy of Prematurity in the Early Treatment for Retinopathy of prematurity Randomized Trial. *Arch Ophthalmol*, 121, Dec, pp
- 43 Saunders RA, Donahue ML, Berland JE, Roberts EL, Powers BV, Rust PF (2000). Non – Ophthalmologists screening for ROP *Br. J Ophthalmol*, 84(2), Feb, pp 130 - 4
- 44 Saunders RA, Bluestein EC, Berland JE, Donahue ML, Wilson ME, Rus PF. (1995) Can Non –ophthalmologist screen for retinopathy of prematurity? *J Pediatr Ophthalmol Strabismus*.32(5), Sep –Oct, pp 302-
- 45 Yen KG, Hess D, Burke B, Johnson RA, Feuer WJ, Flynn JT. (2002) Telephotoscreening to detect ROP: preliminary study of the optimum time to employ digital fundus camera imaging to detect ROP. *J AAPOS*. 6(2), Apr, pp 61 - 3
- 46 Selvin M, Murphy JFA, Daly L, Keefe MO (1997). Retinopathy of prematurity screening, stress related responses, the role of nesting. *Br J Ophthalmol*, pp 762 - 764.
- 47 O'Connor AR, Stephenson T, Johnson A, Tobin MJ, Moseley MJ, Ratib S, Ng Y, Fielder AR. (2002) Long-term ophthalmic outcome of LBW children with and without ROP. *Paediatrics*; 109(1), Jan, pp 12 - 8.
- 48 Theng JT, Wong TY & Ling Y (2000). Refractive errors and strabismus in premature Asian infants with and without ROP. *Sing Med J*; 41(8), Aug, pp 393 - 7
- 49 Cryotherapy for Retinopathy of Prematurity Cooperative Group (2001). Multicenter trial of cryotherapy for retinopathy of prematurity: ophthalmological outcome at 10 years. *Arch Ophthalmol*; 119(8), Aug, pp 1110 - 8
- 50 Terasaki H & Hirose T (2003). Late-onset RD associated with regressed ROP. *Jpn J Ophthalmol*, 47(5), Sept-Oct, pp 492 -7.

- 51 Gurdian SJ, Gehlbach PL, Hunyor AP, Robertson JE (2001). Retinal detachment associated with subthreshold ROP. *J Pediatr Ophthalmol Strabismus*, 38(5), Sep-Oct, pp 279 - 83
- 52 Ritch R, Chang BM & Liebmann JM (2003). Angle closure in younger patients. *Ophthalmology (United States)*, 110(10), Oct, pp 1880 - 9.
- 53 Hunter DG & Repka M (1993) Diode laser photocoagulation for threshold Retinopathy of Prematurity in the Early treatment for Retinopathy of Prematurity. *Ophthalmology*; 100, pp 238 - 244.
- 54 Alistair FA. (2002) Preliminary results of treatment of eyes with high risk prethreshold retinopathy of Prematurity in the Early treatment for Retinopathy of Prematurity randomized trial. *Archives of Ophthalmology* 121, pp 1769 – 1771.
- 55 Capone A, Diaz-Rohena R, Sternberg P, Mandell B, Lambert HM, Lopez PZ (1993). Diode laser photocoagulation for zone 1 threshold Retinopathy of Prematurity. *Am J Ophthalmol*, 116, pp 444 - 450
- 56 McNamara JA, Tasman W, Brown CG (1992). Diode laser photocoagulation retopathy of prematurity - preliminary results. *Arch Ophthalmol*, 110, pp 623 - 624.
- 57 Goggin M, O'Keefe M, (1993) Diode laser for retinopathy of prematurity – early outcome. *Br J Ophthalmol*, 77, pp 559 – 562.
- 58 Cryotherapy for Retinopathy of Prematurity Cooperative Group (1993). Multicenter trial of cryotherapy for retinopathy of prematurity: 3½ year outcome – structure and function. *Arch Ophthalmol*, 111, pp 339 - 344
- 59 Cryotherapy for Retinopathy of Prematurity Cooperative Group (1990) Multicenter trial of cryotherapy for retinopathy of prematurity : one year outcome. *Arch Ophthalmol*, 108, pp 1408 -1416.
- 60 Cryotherapy for Retinopathy of Prematurity Cooperative Group (1990). Multicenter trial of cryotherapy for retinopathy of prematurity : 3-month outcome. *Arch Ophthalmol* , 108, pp195 – 204.
- 61 Cryotherapy for retinopathy of Prematurity Cooperative Group (1988). Multicenter trial of cryotherapy for retinopathy prematurity : *Arch Ophthalmol* , 106 , pp 471 – 479.
- 62 Cryotherapy for Retinopathy of Prematurity Cooperative Group (1988) Multicenter trial of cryotherapy for retinopathy of prematurity: preliminary results. *Pediatrics*, 81(5), pp 697-706.
- 63 Brown GC. Tasman WS, Naidoff M, Schaffer DB, Quinn G, Bhutani VK. (1989) Systemic complication associated with retinal cryoablation for retinopathy of prematurity. *Ophthalmology*, 97, pp 855 – 58.
- 64 Trese MT. (1994) Scleral buckling for retinopathy of prematurity. *Ophthalmology*, 101, pp 23 -26.
- 65 Capone A, Trese MT (2001). Lens sparing vitreous surgery for Tractional 4A ROP retinal detachments, *Ophthalmology*,108, pp 2068 – 70.
- 66 Summers G, Dale L, Phelps MD, Tung B, Palmer E. (1992) Ocular cosmesis in retinopathy of prematurity. *Arch Ophthalmol* ,110, pp 1092 – 97.
- 67 The report of a Joint Working Party of The Royal College of Ophthalmologists and the British Association of Perinatal Medicine. (1996).

Retinopathy of prematurity: guidelines for screening and treatment. *Early Hum Dev* 46(3), pp 239-58.

Appendix 1

LEVELS OF EVIDENCE SCALE

| Level | Strength of evidence | Study design |
|-------|----------------------|---|
| 1 | Good | Meta-analysis of RCT, Systematic review |
| 2 | Good | Large sample RCT |
| 3 | Good to Fair | Small sample RCT |
| 4 | | Non-randomised controlled prospective trial |
| 5 | Fair | Non-randomised controlled prospective trial with historical control |
| 6 | Fair | Cohort studies |
| 7 | Poor | Case-control studies |
| 8 | Poor | Non-controlled clinical series, descriptive studies multi-centre |
| 9 | Poor | Expert committees, consensus, case reports, anecdotes |

(Adapted from Catalanian Agency for Health Technology Assessment & Research, [CAHTAR] Spain)

Appendix 2

CLASSIFICATION OF RETINOPATHY OF PREMATURITY

The International Classification of Retinopathy of Prematurity grades severity of the disease by stages (0-5), location of the disease into zones (1-3) and extent of the disease based on the clock hours (1-12) .

Stages

Stage 0 - mildest form of ROP, with immature retinal vasculature and no clear demarcation of vascularized and nonvascularized retina

Stage 1 - fine, thin demarcation line with no height and thickness appears between the vascular and avascular retina.

Stage 2 - the white line widens into a broad, thick ridge clearly separating the vascular and avascular retina.

Stage 3 - neovascularisation grows into the vitreous on the ridge, on the posterior surface of the ridge or anteriorly toward the vitreous cavity and the ridge has a velvety appearance with a ragged border.

Stage 4 – sub-total retinal detachment beginning at the ridge where the retina got pulled anteriorly into the vitreous by the fibrovascular ridge

Stage 4A - partial retinal detachment not involving the fovea.

Stage 4B - partial retinal detachment involving the fovea.

Stage 5 - total retinal detachment in the shape of a funnel.

Stage 5A - open funnel.

Stage 5B - closed funnel.

Plus disease

"Plus disease" is an indication of activity and is characterised by the appearance of dilatation and tortuosity of the retinal vessels, iris vascular engorgement, pupillary rigidity, and vitreous haze.

Zones

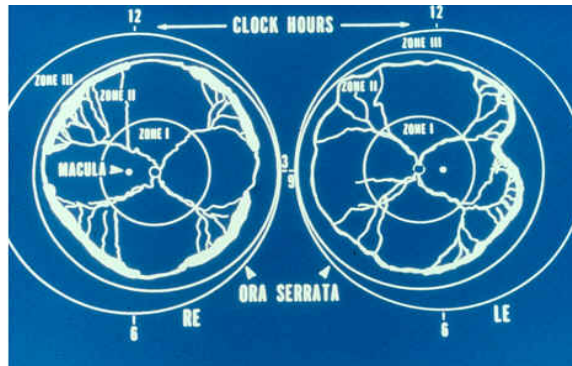
The retinal blood vessels grow out from the optic disk, and the designation by zones corresponds to this vascular development pattern as shown in the diagram below.

Zone 1 – extends from the optic disc to a point double the distance from the disc to the fovea, a radius of 30° .

Zone 2 is a circle surrounding the zone 1 circle with the nasal ora serrata as its nasal border.

Zone 3 - the residual crescent anterior to zone 2

The extent of ROP is recorded as clock hours in each eye according to the relevant zone.



Regressed ROP

Regressed ROP may result in vitreoretinal sequelae producing vascular and retinal changes in the peripheral retina.

Appendix 3

PREPARATION FOR TREATMENT OF RETINOPATHY OF PREMATUREITY

PRE-OPERATIVE PREPARATION:

Preparation of the Parents

The premature baby has a potentially blinding condition, which needs urgent treatment and must be handled with the utmost consideration. The ophthalmologist should discuss the situation with the parents in detail.

Consent

Consent should be obtained by the treating ophthalmologist.

Ideal location for treatment

Neonatal unit is the best location as close supervision and monitoring throughout the procedure can be provided.

Preparation of the environment

1. Move the baby into a single room where the laser procedure is to be performed.
2. The room is closed to all visitors and staff members not looking after the baby.
3. A sign must be displayed on the doors indicating that a laser procedure is taking place and that no one should enter.
4. Doors and windows are shielded to prevent the laser light exiting the room.

Preparation of attending staff members

All staff in the room must wear protective goggles throughout the procedure.

Preparation of equipment

The ophthalmologist will bring the equipment required for the laser treatment and will be responsible for its safe operation and maintenance.

Preparation of the baby

1. Inform the paediatrician and prepare the baby.

2. Check full blood count, electrolytes, and glucose to determine biochemical and haematological state, and correct any significant abnormalities.
3. Baby should be nil by mouth for 4 hours prior to the set time of laser procedure. An IV infusion should be commenced.
4. Dilate the pupils fully by instilling eye drops : 1 drop of 0.5% cyclopentolate and 1 drop of 2.5% phenylephrine or gutt Cyclomydril (0.2% cyclopentolate and 1% phenylephrine) in each eye every 10 minutes 1 hour prior to procedure.
5. Move baby onto a heated table and place the baby in supine position.
6. Intubate and ventilate the baby to ensure a safe airway. Good sedation (e.g. fentanyl) and analgesia (e.g. fentanyl, morphine) during laser procedure are essential since laser treatment can be painful.
7. Maintain the baby on continuous monitoring and hourly recordings of cardio-respiratory status. Experienced staff must be in attendance until baby has fully recovered.

Intraoperative

Monitor vital signs and possible complications during the procedure.

Paediatric postoperative management

1. Wean off ventilation when stable.
2. Maintain intravenous fluid therapy as prescribed.
3. Restart enteral feeds when the baby wakes up.
4. Monitor for signs of feeding intolerance.
5. Continuous monitoring and hourly recording of cardio-respiratory status, blood pressure, SpO₂, and skin temperature.
6. Baby is nursed with eye shield for at least 8 hours to protect from light if on a heated table, or should be protected from direct light by covering the incubator.
7. Observe for oedema of the eyelids, infection, and intra-ocular bleeding.

8. Administer eye drops or ointment as prescribed .
9. Keep parents informed of baby's progress.
10. Follow-up appointments are to be stressed and scheduled accordingly.

Ophthalmic post-operative management

- Mydriatic, antibiotic and steroid drops instilled for a week.
- Examine the retina after a week by which time `plus' disease should show the signs of regression.
- Re-treatment may be needed in selective cases especially if there is still active ROP it is probably not necessary to treat all skip areas.

Appendix 4

CRYOTHERAPY PROCEDURE

- Cryotherapy applications are applied contiguously.
- The cryoprobe is placed trans-sclerally to the avascular zone anterior to the ridge.
- End point of cryotherapy is the appearance of mild whitening. It is important not to apply excessive cryotherapy.
- The entire 360 degrees circumference of the globe is treated under direct visualization.
- Apply the cryo treatment in the temporal retina first where the access is better.
- Avoid applications to the ridge itself when using cryopexy.
- Allow defrosting before removing the cryoprobe to prevent damage to the ocular tissues.

Appendix 5

GENERAL INFORMATION FOR PARENTS

Babies with birth weights less than 1500 gm or those born prematurely 8 weeks or more, should routinely have their eyes examined. This is done to pick up those infants who may develop a disease known as 'Retinopathy of Prematurity' (ROP)

It is important to understand that ROP is a common condition. Most babies only get a mild form of ROP which will resolve completely by itself without affecting the vision. But some babies may progress to advanced form of disease and require treatment. There are various methods of treatment available which are effective and successful.

Prematurity is the main cause of ROP, the more premature the baby is born the greater the risk of developing ROP. The use of oxygen has been implicated but a clear relationship between oxygen therapy and ROP has not been well established. The baby's general condition may also play a role in the development of ROP.

ROP affects the development of blood vessels in the retina of the eye. The retina is the innermost layer at the back of the eye responsible for vision. The blood vessels are not fully developed as the baby is born prematurely. There is a possibility of development of abnormal blood vessels and progress to sight threatening complications. However, in mild forms of ROP, which are very common, vision is not affected and the babies will have complete recovery.

Screening of the premature babies helps in the early diagnosis of ROP especially those with severe ROP, which needs prompt treatment for good outcome.

The screening is usually carried out within a few weeks after birth, and is usually done before the baby has been discharged from the hospital. In some cases babies would need to come back to the eye clinic on an outpatient basis for further examination of the eyes. It is very important that regular examinations are carried out to monitor the progress of the disease and to administer the treatment if indicated.

Please ask your doctor for more information if you need any further information.
